

Temporomandibular Joint Dysfunction in Whiplash Injuries: Association with Tinnitus and Vertigo

Raymond Boniver

Ear, Nose, and Throat Service, Verviers Hospital, Verviers, Belgium

Abstract: Temporomandibular joint dysfunction in whiplash injuries is usual. The author describes the mechanism of this joint dysfunction and the physiopathology of tinnitus and associated balance disorders.

Key Words: balance disorders; temporomandibular joint dysfunction; tinnitus; whiplash

PHYSIOPATHOLOGY OF TEMPOROMANDIBULAR JOINT DYSFUNCTION IN WHIPLASH INJURY

In whiplash injury, the trunk is suddenly projected forward and the head, because of its inertia, is violently thrown backward (unless an adequate headrest is present). Consequently, a hyperextension of the head on the neck is produced (Fig. 1). When this maximum extension is attained, the movement is transformed into a forward displacement, a hyperflexion. In the hyperextension phase, the jaw is flung open because of mandibular inertia. This brings about joint elongation. At the moment of hyperflexion of the head on the thorax with sudden closure of the mouth (either propelled by the cranium or through the effect of the shock of the mandible striking the thorax, the dashboard, or the steering wheel), the condyle compresses the retrodiscal tissues, which may result in an anterior discal displacement.

In the case of a frontal shock, the opposite occurs, with hyperflexion preceding hyperextension. Here, the retrodiscal tissue compression precedes its elongation. A lateral displacement by rotation inclination may also occur [1]. Kaplan and Assael [2] pointed out that the opening of the mouth at the moment of hyperextension

is due to the inertia of the mandible, the displacement of which is slower than that of the cranium, and to the fact that the suprahyoid muscles do not lengthen quickly enough to compensate for the hyperextension of the head.

During the deceleration phase, the head is abruptly hyperflexed, resulting in closure of the mouth. This causes a retrusion of the condyle and an anterior displacement of the disk. According to Hartmann and Cucchi [3], the violent stretching of the external pterygoid causes a simple myostatic trigeminal reflex in the superior belly of the muscle, provoking a reflex contracture with resultant pain at the articular level and an anterior dislocation of the disc.

It is well-known that whiplash injury is accompanied by cervical muscle spasm that, through stimulation of neuroreceptors, causes a reflex alteration of neck posture. The suprahyoid muscles present a hypertonicity that alters the positioning of the mandible relative to the maxilla, thus resulting in a malocclusion. The neuroreceptors of the periodontal ligament and of the temporomandibular joint (TMJ) then are alerted and send their response to the central nervous system, which increases muscular tension through a reflex pathway.

Benham [2] demonstrated through a mathematical model that when the victim of a whiplash injury is wearing a seat belt, the energy transmitted to the head and neck is greatly increased because of the limitation of the movement of the thorax, thus resulting in an increased amplitude of flexion of the head in relation to the rest of the body.

Although certain authors deny that TMJ problems are associated with whiplash injury [4–11], others amply

Reprint requests: Dr. Raymond Boniver, Rue de Bruxelles, 21, B-4800 Verviers, Belgium. Phone: 32(87)22.17.60; Fax: 32(87)22.46.08; E-mail: r.boniver@win.be

This research was presented at the Twenty-Ninth Neuro-otological and Equilibrimetric Society Congress, Bad Kissingen, Germany, March 15–17, 2002.

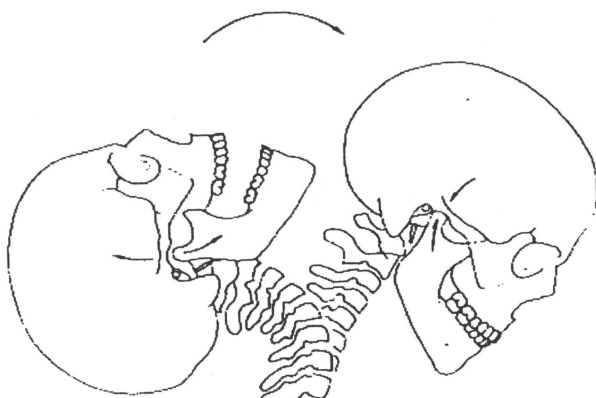


Figure 1. Whiplash injury. On extension, the temporomandibular joint elongates (abrupt opening of the mouth). On flexion, the joint is compressed (sudden buccal closure).

demonstrate evidence of the relationship between the two [12–18]. Attention is drawn to the comparative studies performed by Kolbinson et al. [19–21]. They show that patients having had a whiplash injury present more TMJ problems than do those who have not. Also, the evolutionary prognosis of patients presenting TMJ problems after whiplash is more guarded than in those patients who have not been subjected to such trauma. Further, symptoms persist regardless of whether the medicolegal aspects of the case have been settled.

Magnetic resonance imaging studies of the TMJ in 87 consecutive cervical whiplash patients who presented with TMJ symptoms demonstrate abnormalities [16]: 72% disc displacement with reduction, 15% disc displacement without reduction, 69% joint effusion, 51% soft-tissue inflammation or edema, and 95% total TMJ abnormalities.

No control MRI study that included patients with TMJ disorders in the absence of a whiplash injury was conducted, so one cannot exclude an aggravation of a preexisting condition. However, the fact that previously asymptomatic patients became symptomatic after an accident lends credence to the probable relationship between the TMJ disorder and the whiplash.

From this group of studies emerges an interrelation of cause and effect between whiplash and TMJ disorders. In effect, whiplash is capable of inducing joint lesions as well as posttraumatic malocclusions. Systematic examination of the TMJ after whiplash can be obtained and documented in medical statements, through radiographs, and by MRI, so as to permit more significant comparative studies.

An earlier diagnosis would permit inception of a multidisciplinary treatment program so as to ease patients' symptoms rapidly and definitively. The sig-

nificance of psychological factors must be kept in mind, recalling that TMJ problems are interwoven in a tableau of an often minor cervical sprain in which the "neurotic" context has its own importance.

PHYSIOPATHOLOGY OF TINNITUS LINKED TO TMJ DISORDERS

To open the eustachian tube, the tensor veli palatini muscle brings about a lateral movement of the internal pterygoid muscle and its interposed fascia. The modifications of intratympanic pressure resulting from auditory tube dysfunction could explain the hearing loss and tinnitus encountered in TMJ disorders. Central factors appear to be preponderant in the origin of spasticity of the masticatory muscles.

Thus, an increased excitability, in particular of the motor neurons of the muscles innervated by the trigeminal nerve, can trigger, through the participation of the levator fibers of the internal pterygoid (clenching of the teeth), a malfunction in the regulation of tympanic membrane tension (action of the tensor tympani), causing tinnitus. The malfunction of the tensor veli palatini muscle affecting tubal patency can produce the sensation of a blocked ear.

In these conditions, the diagnostic value of muscle palpation becomes evident: The painful palpation of the internal pterygoid muscle would point toward a masticatory origin of the tinnitus. Resolution of muscle spasm or tension with physiotherapy will be indicated in such cases.

PHYSIOPATHOLOGY OF BALANCE DISORDERS ASSOCIATED WITH TMJ DYSFUNCTION IN WHIPLASH INJURY

The trigeminal hypersensitivity engendered by TMJ problems may perturb the oculocephalogyric system. In a trauma patient with constant complaints of balance problems and presenting a negative workup, a possible dysfunction of the masticatory apparatus secondary to the trauma must be suspected. At the time of cervical postural examination, trigger points along the sternocleidomastoid must be routinely sought, particularly in cases of idiopathic vertigo.

An overstimulation of trigeminal origin could modify the physiology of head posture. In the same manner as a "computer virus," these afferents of parafunctional origin would disturb the harmonious function of the superior colliculus in the regulation of visual fixation, resulting in a vertiginous sensation. The epidemiological findings seem to corroborate the importance of the parafunctional factor in the development of vertigo of masticatory origin in TMJ disorders, such as is perceived at the physiopathological level.

CONCLUSION

As part of the workup of whiplash injuries, the function of the TMJ and troubles of tonicity of the corresponding muscles are important elements for examination. Anomalies at this level can be implicated in the origin of associated tinnitus and vertigo. Accurate diagnosis leads to appropriate treatment and ultimate clearing of the symptoms.

REFERENCES

- Gola R, Chassegras C, Orthlieb JD. *Syndrome Algo-dysfonctionnel de l'Appareil Manducateur*. Paris: Masson, 1995.
- Kaplan AS, Assael LA. *Temporomandibular Disorders, Diagnosis and Treatment*. Philadelphia: Saunders, 1994.
- Hartmann F, Cucchi G. *Les dysfonctions crano-mandibulaires (SADAM)*. Berlin: Springer-Verlag, 1993.
- Zafar H. Integrated jaw and neck function in man. Studies of mandibular and head-neck movements during jaw opening-closing tasks. *Swed Dent J Suppl* 143:1-41, 2000.
- Howard RP, Benedict JV, Raddin JH Jr, Smith HL. Assessing neck extension-flexion as a basis for temporomandibular joint dysfunction. *J Oral Maxillofac Surg* 50(4):427-428, 1992.
- Bedrone B, Jammet P, Chossegras C, et al. Temporomandibular joint pain-dysfunction syndrome after whiplash injury. Medico-legal problems in common law. *Rev Stomatol Chir Maxillofac* 93(6):408-413, 1992.
- Heise A, Laskin DM, Gervin AS. Incidence of temporomandibular joint symptoms following whiplash injury. *J Oral Maxillofac Surg* 50(8):825-828, 1992.
- Bergman H, Andersson F, Isberg A. Incidence of temporomandibular joint changes after whiplash trauma: A prospective study using MR imaging. *AJR Am J Roentgenol* 171(5):1237-1243, 1998.
- Mckay DC, Christensen LV. Whiplash injuries of the temporomandibular joint in motor vehicle accidents: Speculations and facts. *J Oral Rehabil* 25(10):731-746, 1998.
- Ferrari R, Leonard MS. Whiplash and temporomandibular disorders: A critical review. *J Am Dent Assoc* 129(12):1739-1745, 1998.
- Ferrari R, Schrader H, Obelieniene D. Prevalence of temporomandibular disorders associated with whiplash injury in Lithuania. *Oral Surg Oral Med Oral Pathol Oral Radiol Endod* 88(2):115-116, 1999.
- Weinberg S, Lapointe H. Cervical extension-flexion injury (whiplash) and internal derangement of the temporomandibular joint. *J Oral Maxillofac Surg* 45(8):653-656, 1987.
- Goldberg HL. Trauma and the improbable anterior displacement. *J Craniomandib Disord* 4(2):131-134, 1990.
- Burgess J. Symptom characteristics in TMD patients reporting blunt trauma and/or whiplash injury. *J Craniomandib Disord* 5(4):251-257, 1991.
- Burgess JA, Kolbinson DA, Lee PT, Epstein JB. Motor vehicle accidents and TMDs: Assessing the relationship. *J Am Dent Assoc* 127(12):1767-1772 and 1785, 1996.
- Garcia R, Arrington JA. The relationship between cervical whiplash and temporomandibular joint injuries: An MRI study. *Cranio* 14(3):233-239, 1996.
- Krogstad BS, Jokstad A, Dahl BL, Soboleva U. Somatic complaints, psychologic distress, and treatment outcome in two groups of TMD patients, one previously subjected to whiplash injury. *J Orofac Pain* 12(2):136-144, 1998.
- Friedman MH, Weisberg J. The craniocervical connection: A retrospective analysis of 300 whiplash patients with cervical and temporomandibular disorders. *Cranio* 18(3):163-167, 2000.
- Kolbinson DA, Epstein JB, Burgess JA. A comparison of TMD patients with or without prior motor vehicle accident involvement: Initial signs, symptoms and diagnosis characteristics. *J Orofac Pain* 11(3):206-214, 1997.
- Kolbinson DA, Epstein JB, Senthilselvan A, Burgess JA. A comparison of TMD patients with or without prior motor vehicle accident involvement: Treatment and outcomes. *J Orofac Pain* 11(4):337-345, 1997.
- Kolbinson DA, Epstein JB, Senthilselvan A, Burgess JA. Effect of impact and injury characteristics on post-motor vehicle accident temporomandibular disorders. *Oral Surg Oral Med Oral Pathol Oral Radiol Endod* 85(6):665-673, 1998.